

EMERGENCY PRESENTATIONS:

1. Unstable Vital Signs
 - Fever > 101° F
 - Hypotension
 - Tachycardia > 120 bpm x 4 hours
 - Tachypnea
 - Hypoxia
 - Decreased urine output
2. Bright Red Blood by Mouth or Rectum, Melena, Bloody Drainage
3. Abdominal Pain or Colic > 4 hours
4. Nausea ± Vomiting > 4 hours
5. Vomiting ± Abdominal Pain

BARIATRIC COMPLICATIONS:

- Intra-Abdominal Bleeding
- Leaks and Sepsis
- Obstruction
- Pulmonary Embolism
- Vomiting ± Abdominal Pain
- Abdominal Compartment Syndrome

IMPORTANT: KNOW THE ANATOMY: IT CAN BE VERY CONFUSING!
Patients often don't know which procedure they have had, and surgeons vary the procedure dramatically. If you're not the primary surgeon, call the surgeon who performed the procedure.

Principles to Guide Management of Bariatric Emergencies

I. Critical Time Frame

- Diagnose within 6 hours
- To OR within 12-24 hours

II. Critical Warnings

- Call bariatric surgeon early; if not available, call general surgeon on call
- These are not typical abdominal surgery patients; they do not exhibit expected or typical signs and symptoms, and they have no physiological reserve to weather complications.
- NG-tube:
 - Avoid "blind placement" due to risk of perforation
 - Will not decompress the distal stomach
- Avoid NSAIDs, ASA, Plavix, Steroids:
 - Greater risk of ulcer, band erosion and perforation
 - Place on PPI for gastric erosion safeguard
- Thiamine deficiency:
 - Initially avoid glucose in IV fluids (unless hypoglycemia is confirmed)
 - Use RL or NS w/ 100 ampule of multivitamin
 - Can result in Wernicke's syndrome, characterized by ataxia, confusion, blurred vision. IV dextrose will increase the risk of permanent neurologic impairment.
- Avoid overloading the gastric pouch with oral fluids or contrast—should only give 6 oz.

Initial Assessments

1. Physical exam and vital signs - may need to be serial.
2. Labs:
 - CBC
 - Comprehensive Chemistry Profile
 - Amylase
3. Imaging:
 - Chest X-Ray
 - CT of Abdomen with oral contrast
 - CT of Chest with IV contrast

Hospital Management of the Bariatric Surgery Patient

"FAST HUG"

- **FOOD:** Establish enteral or parenteral nutrition within 48 hours
- **ANALGESIA:** Control pain for patient comfort
- **SEDATION:** If on ventilator to prevent self-extubation
- **THROMBO-EMBOLIC PROPHYLAXIS:** Mechanical and chemical
- **HEAD-OF-BED ELEVATED** 30° for aspiration risk
- **ULCER PROPHYLAXIS:** Proton pump inhibitor
- **GLUCOSE CONTROL:** Tight control with glucose < 150

● INTRA-ABDOMINAL BLEEDING

I. Emergency Presentation

Bright Red Blood Oral or Rectal, Melena, Bloody Drainage, Tachycardia, Hypotension, Fainting

- < 48 hrs postop indicates potential bleed from staple line
- > 48 hrs postop indicates potential marginal ulcer hemorrhage
- Bleeding via oral route indicates potential pouch source
- Melena or bleeding via rectal route indicates potential duodenal ulcer or distal stomach or bowel source.

II. Emergency Assessment and Treatment

- Give 1000 mL NS fluid bolus
- Stop Anticoagulants, ASA or Plavix
- Type/Crossmatch PRBCs; may need FFP or platelets
- Serial Hct/Hgb
- Frequent Vital Signs
- Monitor Urine Output
- Check Renal Profile
- Good IV access; may need central line

III. To Surgery if:

- Hypotension
 - Drop in Hct of 10%
 - Falling Hct despite transfusion
 - Tachycardia > 120 x 4 hrs despite fluid bolus or blood transfusion
- *NOTE: Consider EGD in OR under general anesthesia to control airway. Inject and cautery by EGD. Check for perforation. HIGH RISK! Visualization difficult if brisk bleed.*

● PULMONARY EMBOLISM

I. Emergency Presentation

- Unstable vital signs with tachypnea ± chest pain

II. Emergency Assessment

- IV contrast-enhanced chest CT
- Presentation of an intra-abdominal complication such as leak or closed-loop obstruction is often similar to that of PE.*

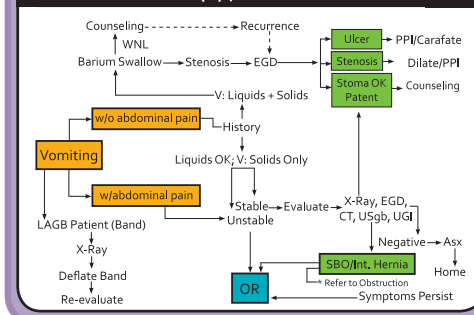
● VOMITING ± ABDOMINAL PAIN

I. Emergency Presentation

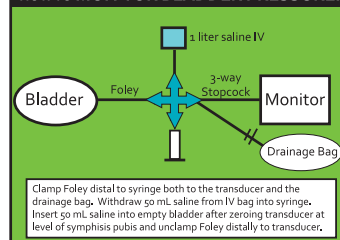
Vomiting associated with abdominal pain needs prompt surgical evaluation and observation until resolved or surgical exploration.

I. Emergency Assessment and Treatment

CLINICAL PATHWAY FOR EVALUATION OF VOMITING (V):/ABDOMINAL PAIN



HOW TO MONITOR BLADDER PRESSURE:



● ABDOMINAL COMPARTMENT SYNDROME

I. Emergency Presentation

- Progressive respiratory insufficiency
- Renal failure
- Intra-abdominal hypertension (25-mm or mmHG bladder pressure)
- Associated with end-organ failure
- Can occur with intra-abdominal sepsis, bleeding or obstruction

II. Emergency Treatment → To Surgery

- Open the abdomen to decompress
- Place VAC dressing

● LEAKS AND SEPSIS

I. Emergency Presentation

- Unstable vital signs within 72 hours of bariatric surgery
- Persistent and progressive tachycardia (>120 bpm > 4 hrs) is the most sensitive indicator of potential surgical emergency.
 - Signs of sepsis/leak may be subtle at first and may need to rule out hypovolemia, atelectasis, bleeding, pulmonary embolism (PE), obstruction and/or leak.
- Unstable vital signs at presentation are all signs of sepsis/leak, especially within 72 hours of bariatric surgery: Fever > 101° F, hypotension, tachycardia, tachypnea, hypoxia, decreased urine output.
- Presentation of an intra-abdominal complication, such as leak, is often similar to that of PE. Once PE is ruled out (w/IV contrast-enhanced chest CT), consider immediate surgical exploration.
- A negative abdominal CT does not definitively rule out a complication such as a leak. Abdominal series and gastrografin swallow can be negative even when there is a leak.

II. Emergency Treatment

- Conservative nonoperative management of leaks may be considered if contained leak/abscess is well drained internally or externally with communication to drain documented by imaging and ONLY if the patient is stable clinically (T < 101° F, pulse < 120 bpm, WBC < 15,000, normal renal and respiratory function).
- OTHERWISE:
 - Surgical exploration

● OBSTRUCTION

I. Emergency Presentation

- Abdominal Pain or Colic > 4 hours
 - Common postop complaint. Duration of more than 4 hours, or associated with vomiting, requires surgeon evaluation and observation until resolved or treated. CT/UGI diagnostic in most cases, but not all.
 - No place for NG-tube or conservative management.
 - Acute bleed indicates potential obstruction due to clots in GI tract which may cause perforation.
 - Consider CT of abdomen with oral contrast or barium UGI with small-bowel follow-through to the colon with contrast to assess for possible obstruction.
 - Consider EGD to (A) rule out gastric outlet obstruction or (B) remove gastrografin contrast prior to anesthesia to prevent aspiration.
 - X-rays, labs and physical exam often negative in patients with obstruction.
 - Closed-loop obstructions and internal hernias are a risk after gastric bypass and may be lethal if dead bowel. Bowel can become ischemic in six hours.
 - Adhesions may cause bowel obstructions in any patient after abdominal surgery and be unrelated to bariatric surgery.
 - Beware of RED HERRINGS. Gallstones on ultrasound appear to be etiology while the real issue is dead bowel secondary to closed-loop obstruction.
 - Beware of aspiration of gastrografin or CT contrast - consider awake endotracheal intubation or EGD prep.

Roux-en-Y Gastric Bypass Three Sites for Internal Hernias:

Fig. 1 Potential mesenteric openings that could lead to internal hernia after Roux-en-Y gastric bypass. (A) Transverse mesocolon defect. (B) Petersen hernia (space between mesentery of Roux limb and transverse mesocolon). (C) Jejunojunostomy mesenteric defect.

With permission: J Lap Endo Adv Surg Tech 2000, 10: 173-5

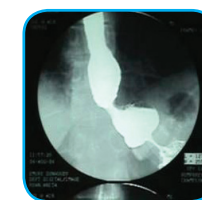
II. Emergency Treatment

- Presentation of an intra-abdominal complication, such as closed-loop obstruction, is often similar to that of PE. Once PE is ruled out (e.g., by IV contrast-enhanced chest CT) consider immediate surgical exploration.
- Dilated distal stomach or contrast in remnant = obstruction → requires immediate decompression.

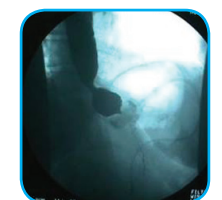Adjustable Gastric Band

- If nausea and vomiting is present, obtain flat plate of abdomen, with band tilted up compared to spine, and barium swallow to assess for possible stenosis or obstruction.
- If slip seen on x-ray → urgent deflate, possibly operate
- To deflate the band, ask patient where their port is located and should be able to palpate on abdominal wall or use fluoroscopy. Can also see it on flat-plate x-ray. Use sterile prep under local. Insert non-coring Huber needle similar to that used for port-a-caths, as the system is under pressure and will leak. Remove as much fluid as possible, then re-evaluate symptoms and findings.
- Maximum band volume is 4-14 mL depending on model.

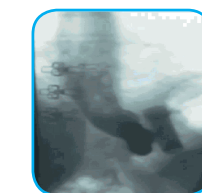
Adjustable Gastric Band Obstructions



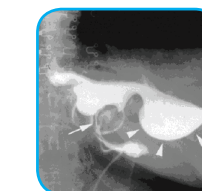Normal LAGB - Band Tilted Up



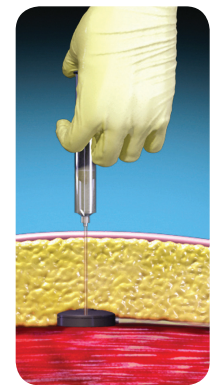
LAGB Too Tight - Normal Tilt



LAGB Slippage - Posterior



LAGB Slippage - Anterior



Deflate Band with Huber Needle

For more information, please visit www.asmbms.org